

# Thyrolingual Trunk Arising from Common Carotid Artery- A Case Report

SANTHOSH KUMAR NOCHIKATTIL<sup>1</sup>, T P SAJITH BABU<sup>2</sup>, SUDHEESH MANOHARAN<sup>3</sup>

## ABSTRACT

Superior Thyroid Artery (STA) usually arises from the ventral surface of the External Carotid Artery (ECA) just below the level of tip of greater cornu of hyoid bone and it runs anteriorly, downwards and medially. Lingual artery arises at the level of tip of greater cornu of hyoid bone and it runs anteriorly, upwards and medially. Rarely, both STA and lingual artery may originate as a common trunk called thyrolingual trunk. But a thyrolingual trunk arising from Common Carotid Artery (CCA) is very rare. We report a case of patient diagnosed to have carcinoma of right lower alveolus with nodal recurrence; with thyrolingual trunk arising from the medial aspect of CCA, which was detected incidentally during neck dissection.

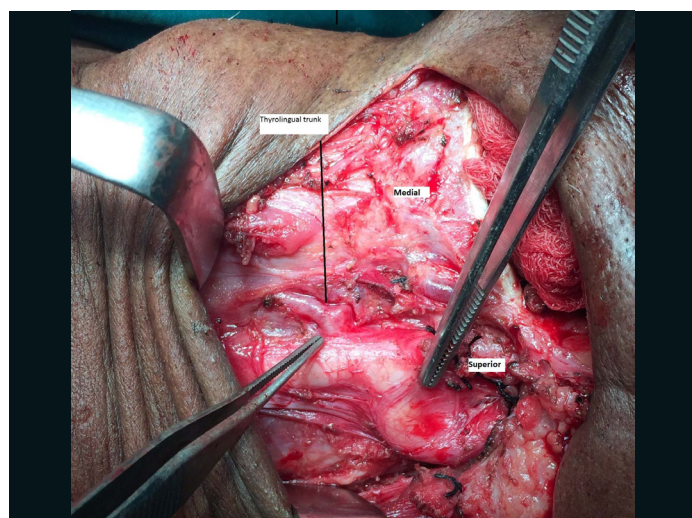
**Keywords:** Anatomical anomaly, Lingual artery, Superior thyroid artery

## CASE REPORT

A 65-year-old male was presented with complaint of swelling on left side of the neck for last two months. On examination, there was a left Level II lymph node of size 2x3 cm. The lymph node was hard in consistency and had a restricted mobility. The patient was a previously treated case of carcinoma of right lower alveolus and was treated with segmental mandibulectomy, right side selective neck dissection and pectoralis major myocutaneous flap reconstruction in the year 2000. The patient also had received adjuvant radiotherapy in the same year and he was under regular follow up since then.

The Fine Needle Aspiration Cytology from the lymph node showed metastatic squamous cell carcinoma. An ultrasound of the neck showed 2x3 cm lymph node with necrosis and calcification and was abutting internal jugular vein. An upper aerodigestive tract endoscopy and chest imaging revealed no separate lesion.

A modified radical neck dissection was done for clearing Level I, II, III, IV and V and left internal jugular vein. Intraoperatively, we found that thyrolingual trunk was arising from medial aspect of left CCA, 10 mm below the carotid bifurcation. The STA was going downwards and the lingual artery was going upwards [Table/Fig-1]. The postoperative period was uneventful and the patient is under regular follow up.



[Table/Fig-1]: Showing thyrolingual trunk arising from common carotid artery.

## DISCUSSION

The left CCA arises from the arch of the aorta and the right CCA arises from the brachiocephalic artery. Both left and right CCA ascend posterolaterally within the carotid sheath and divide into ECA and Internal Carotid Artery (ICA) at the level of upper border of thyroid cartilage. The ECA runs anteromedially and the ICA runs posterolaterally. The CCA and ICA usually do not give off any branches in the neck. Very rarely, CCA may give rise to thyroidea ima artery before bifurcation. However, ECA usually gives off eight branches including STA, lingual artery, ascending pharyngeal artery, facial artery, occipital artery, posterior auricular artery, maxillary artery and superficial temporal artery [1-3].

According to Hollinshead H, STA arises from CCA in 16% of cases [1]. However, a study conducted by Natsis K et al., on Caucasian Greeks, the STA was found to originate from carotid bifurcation and CCA together in 61% of cases and in only 39% of cases, it was originating from ECA. They also noted that in 24% of cases, thyrolingual trunk was present [4]. However, in another study by Ongeti KW and Ogengo JA in Kenyan population, the STA was found to originate from CCA in only 13% of cases. In 80% of cases, it was found to be arising from ECA [5].

In a study conducted by Anagnostopoulou S and Mavridis I on the emerging pattern of human STA, they found that left STA arises approximately 2 mm closer to CCA bifurcation as compared to right STA. In our case, we found the thyrolingual trunk arising from CCA on left side [6].

In 2007, Budhiraja V and Rastogi R reported a case of thyrolingual trunk arising from left CCA, 2 cm below the bifurcation [7]. Lippert H and Pabst R reported that the incidence of thyrolingual trunk arising from CCA was less than 0.1% [8]. In 2013, Kapre M et al., from India reported two cases of thyrolingual trunk, among them, one was arising from CCA, 17 mm below the bifurcation and the other was arising from the carotid bifurcation [9]. Lemaire V et al., reported a case of thyrolingual trunk arising from right CCA, 30 mm below the carotid bifurcation [10].

It is very important for the surgeons to know the normal anatomy and the variations of carotid artery and its branches. Otherwise it can lead to accidental haemorrhage during surgery that may often be fatal. All the head and neck surgeons who do neck dissection and ECA ligation should be aware of the thyrolingual trunk that may arise from the common carotid or carotid bifurcation. During ECA ligation for haemorrhage due to Head and Neck cancers or following

surgeries like tonsillectomy or juvenile nasopharyngeal angiofibroma or any other vascular tumours, it is a common practice to identify ECA with branches and to ligate above the origin of STA. If the surgeon is not aware of the variations, it can lead to disasters. It is also important to know the anatomic variations for giving intra-arterial chemotherapy.

## CONCLUSION

Variations in branching pattern of carotid artery are not very uncommon. Therefore, it is essential for the surgeons to be aware of these normal anatomic variations to avoid complications during and after the surgery.

## REFERENCES

- [1] Hollinshead WH. Anatomy for surgeons: Volume 1, The Head and Neck. Plastic and Reconstructive Surgery. Philadelphia: Lippincott Williams and Wilkins, 1968.
- [2] Standing S. Gray's anatomy: the anatomical basis of clinical practice, 41<sup>st</sup> Ed. New York: Elsevier, 2016.
- [3] Kumar AP, Reddy DK, Jyothi P. Unusual branching of left common carotid artery. Int J Biol Med Res. 2014;5(4):4603-06.
- [4] Natsis K, Raikos A, Foundos I, Lazaridis N, Njau SN. Superior thyroid artery origin in Caucasian Greeks: A new classification proposal and review of literature. Clin Anat. 2011;24(6):699-705.
- [5] Ongeti KW, Ogengo JA. Variant origin of the superior thyroid artery in Kenyan population. Clin Anat. 2012;25(2):198-202.
- [6] Anagnostopoulou S, Mavridis I. Emerging patterns of the human superior thyroid artery and review of the clinical anatomy. Surg Radiol Anat. 2014;36(1):33-38.
- [7] Budhiraja V, Rastogi R. Variant origin of thyrolingual trunk from left common carotid artery. Int J Anat Variaton. 2010;3:44-45.
- [8] Lippert H, Pabst R. Arterial Variations in Man. Classification and frequency, JF Bergan variag: Munchen: 1985.
- [9] Kapre M, Mangalgiri AS, Mahore D. Study of thyro-lingual trunk and its clinical relevance. Indian J Otolaryngol Head Neck Surg. 2013;65(2):102-04.
- [10] Lemaire V, Jacquemin G, Medot M, Fissette J. Thyrolingual trunk arising from the common carotid artery: A case report. J Surg Radiol Anat. 2001;23:135-37.

### PARTICULARS OF CONTRIBUTORS:

1. Assistant Professor, Department of Surgical Oncology, Malabar Cancer Center, Thalassery, Kerala, India.
2. Associate Professor, Department of Surgical Oncology, Malabar Cancer Center, Thalassery, Kerala, India.
3. Senior Resident, Department of Surgical Oncology, Malabar Cancer Center, Thalassery, Kerala, India.

### NAME, ADDRESS, E-MAIL ID OF THE CORRESPONDING AUTHOR:

Dr. Santhosh Kumar Nochikattil,  
Assistant Professor, Department of Surgical Oncology, Malabar Cancer Center,  
Moozhikkara PO, Thalassery-670103, Kerala, India.  
E-mail: dr.santhosh82@gmail.com

FINANCIAL OR OTHER COMPETING INTERESTS: None.

Date of Submission: **Jul 27, 2016**  
Date of Peer Review: **Aug 11, 2016**  
Date of Acceptance: **May 17, 2017**  
Date of Publishing: **Aug 01, 2017**